

Descriptions of Polyps and Epidermal Papillomas in Three Bivalve Mollusk Species

JOHN C. HARSHBARGER

CASE I: HYPERPLASTIC POLYP ON THE FOOT OF A FRESHWATER MUSSEL, *ANODONTA CALIFORNIENSIS*

Polypoid growths of the foot, mantle, and pericardium have been found repeatedly in bivalve molluscs. These growths (reviewed by Pauley, 1969; Sparks, 1972) generally are composed of essentially normal tissues and have been variously interpreted.

Forty-seven (15.7 percent) of 299 freshwater mussels, *Anodonta californiensis*, with foot lesions were collected by Gilbert B. Pauley from the Columbia River on the Hanford Energy Research and Development Administration Reservation in 1965 or 1966 and have been previously described (Pauley, 1967a, b, 1969). A representative specimen from this series was contributed to the Registry of Tumors in Lower Animals (RTLA 142).

The growth was 3-4 mm in diameter and extended slightly more than 2 mm beyond the surface of the foot. The gross surface, as seen with a hand lens, had a slightly sculptured texture, similar to that of the normal areas of the foot. The growth was very slightly constricted at the point of attachment.

Microscopically the growth appeared to be an extension of normal foot elements (Fig. 1). Muscle fasciculi from the normal area extended into the base of the growth and normal muscle cut in all three planes was the principal tissue throughout (Fig. 2). The basic arrangement was preserved except that as the muscle fibers fanned out from the base they were considerably further apart and the resulting space was largely occupied by fibrous connective tissue. Blood vessels were normal as regards

size, frequency, and the thickness of the vessel walls. The peripheral one-fourth of the growth was heavily occupied by normal elongate glands, filled with basophilic granular product, extending up into the surface papillae (Fig. 3). The papilliferous surface was composed of a normal simple ciliated columnar epithelium (Fig. 4).

The cause of these lesions is unknown, but the basically normal arrangement of normal cell types rules out neoplasia. The two tissues that had to have proliferated to provide the extra bulk of covering were the fibrous connective tissue and the surface epithelium. The fanning out of muscle from the point of attachment suggests that muscle was pulled into the area as if an injury had caused the surface to

buckle outwardly. The remaining spaces, according to this model, were then filled with scar tissue and the surface epithelium and associated gland cells proliferated normally.

In conclusion, these lesions are interpreted as traumatic polyps composed of muscle and scar tissue overlain with normal epithelium and associated gland cells.

CASE II: BENIGN MESENCHYMAL POLYP ON THE MANTLE OF A PACIFIC OYSTER, *CRASSOSTREA GIGAS*

A Pacific oyster, *Crassostrea gigas*, with a large pedunculated growth attached to the mantle was discovered in Little Skookum Inlet, Puget Sound, Wash. The specimen was contributed



Harshbarger

John C. Harshbarger is with the Registry of Tumors in Lower Animals, National Museum of Natural History, Smithsonian Institution, Washington, DC 20560.

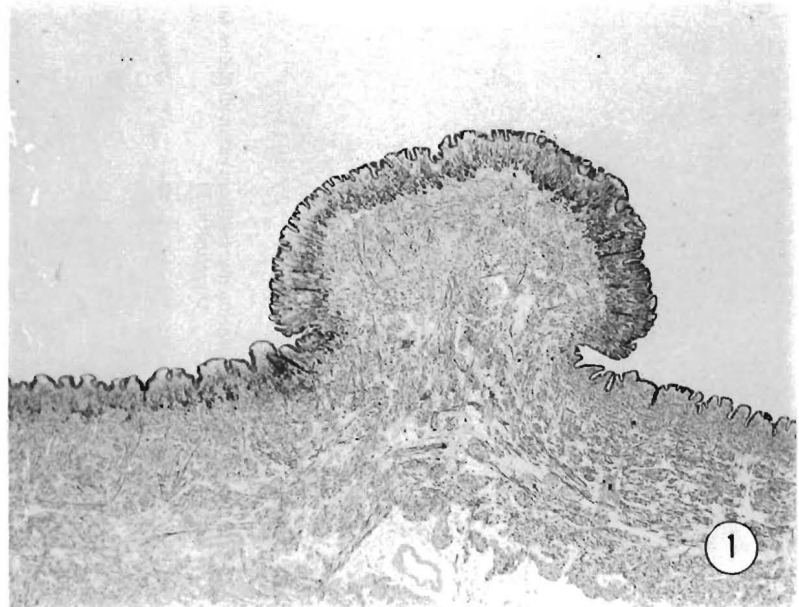


Figure 1.—Polypoid growth extending from the foot. 2.5×.

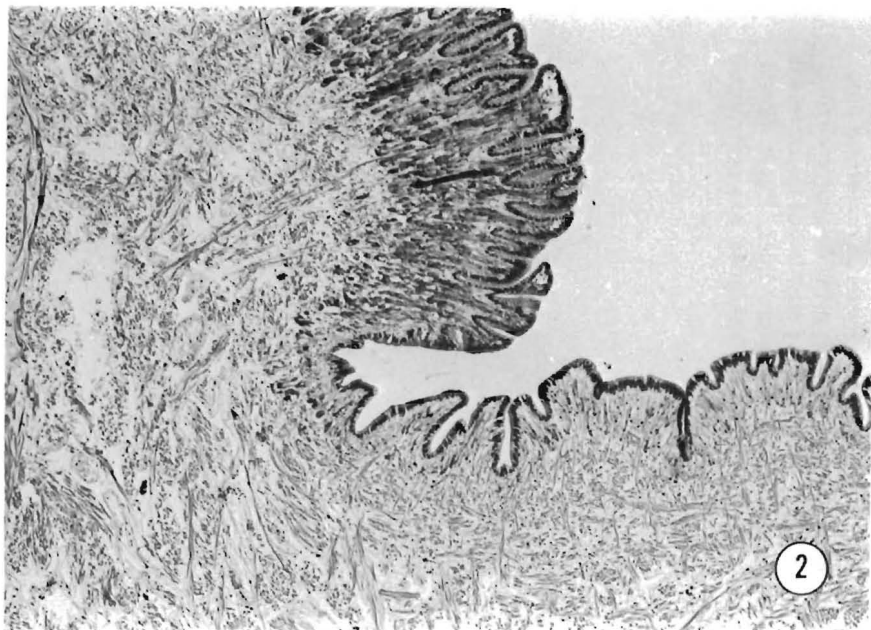


Figure 2.—Fasciculi of normal appearing muscle fibers cut in all planes fan out from the base of the growth. 10 x.

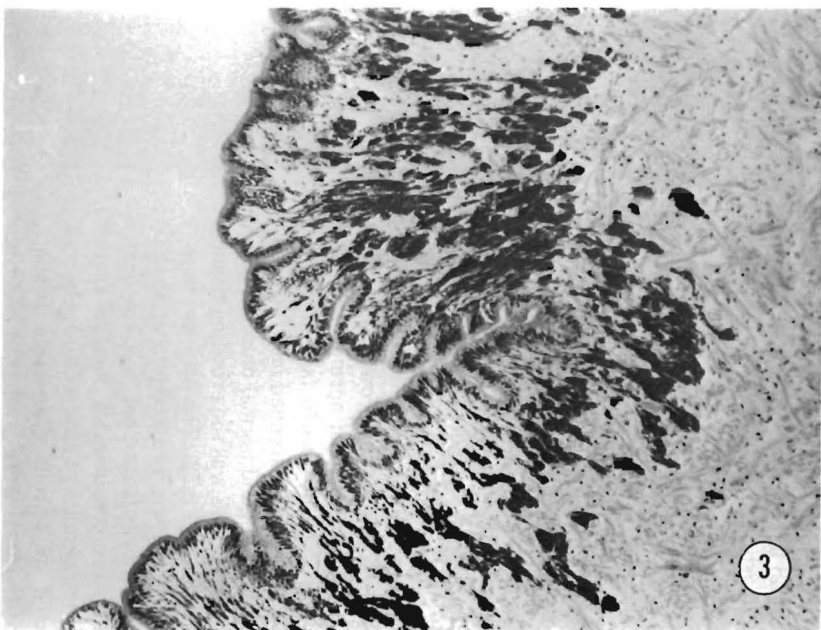


Figure 3.—Normal appearing, product filled, glands extend into surface papillae of normal and tumor epithelium. 27 x.

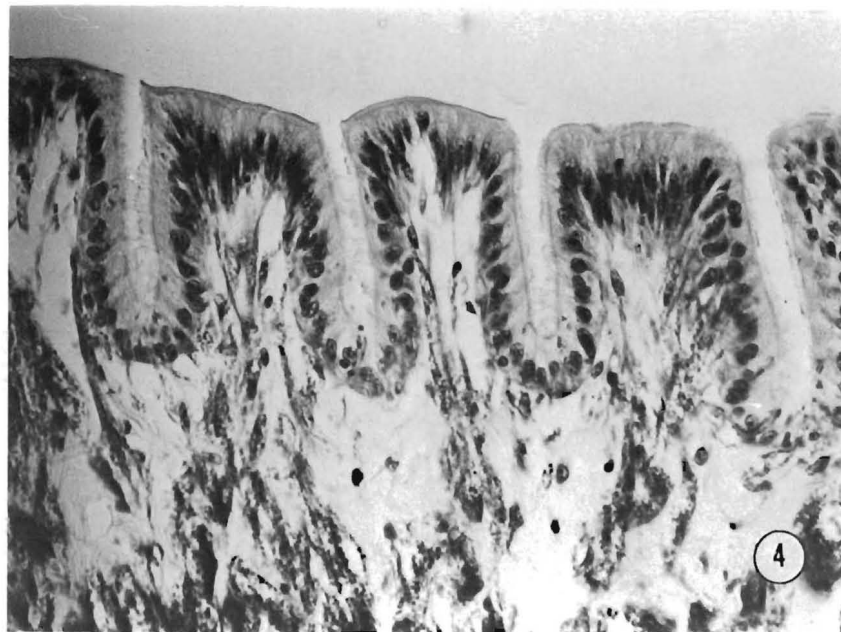


Figure 4.—Normal appearing, simple, columnar, ciliated epithelial border of tumor. 100 x.

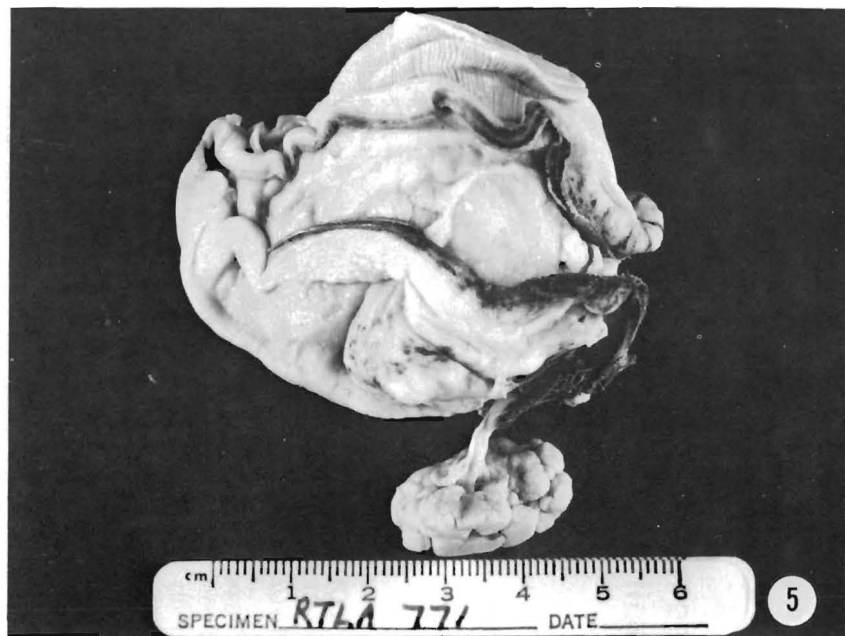

Figure 5.—Stalked polyp extending from mantle.

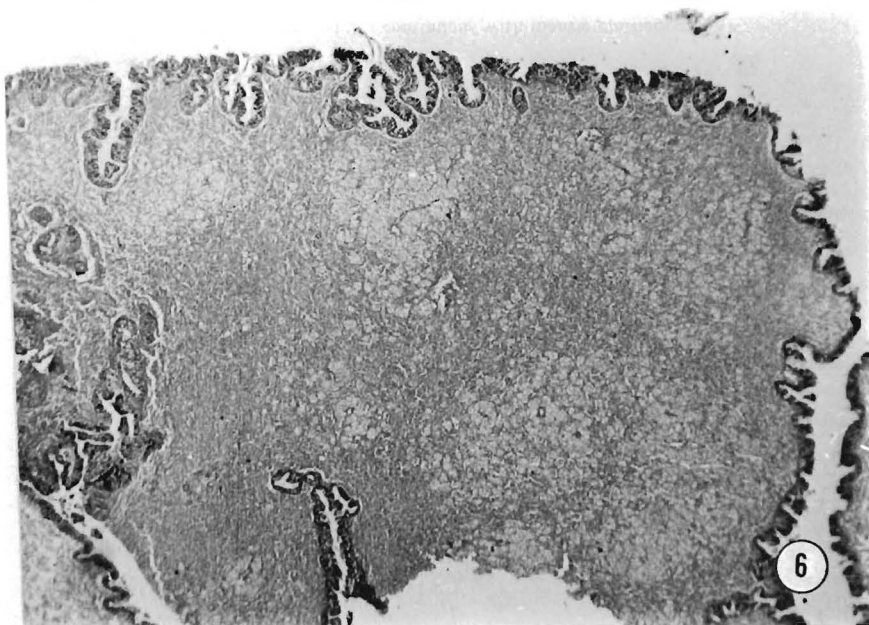


Figure 6.—Histological overview of one lobe showing Leydig component (light areas), fibrous component (darker areas), and cryptal epithelial surface. 4x.

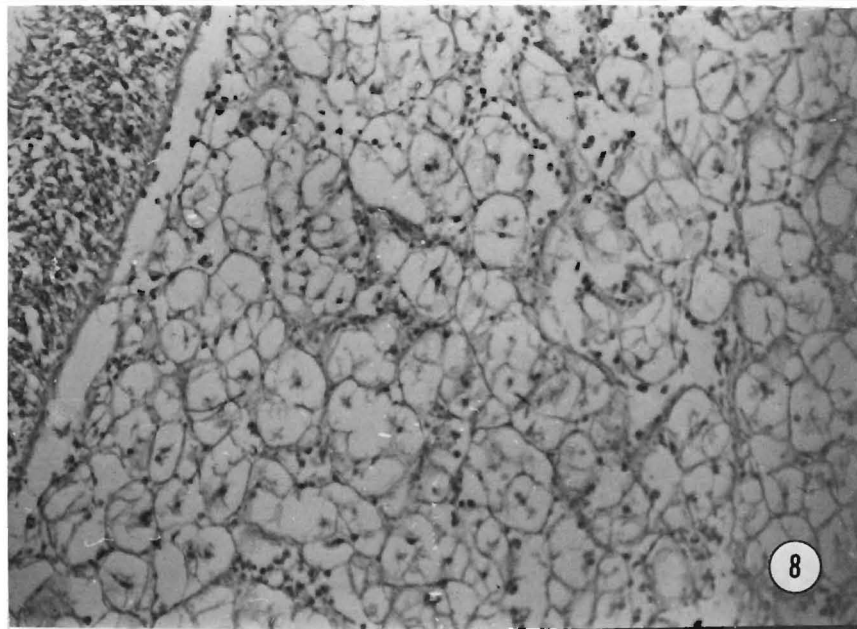


Figure 8.—Normal Leydig (vesiculated connective) tissue. 40x.

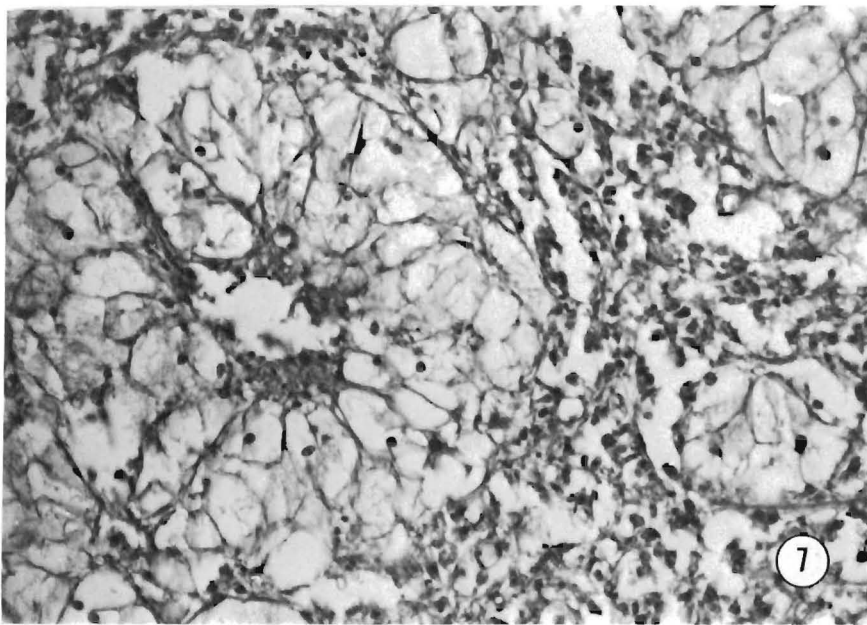


Figure 7.—Pseudorosette of Leydig tissue within fibrous stroma. 100x.

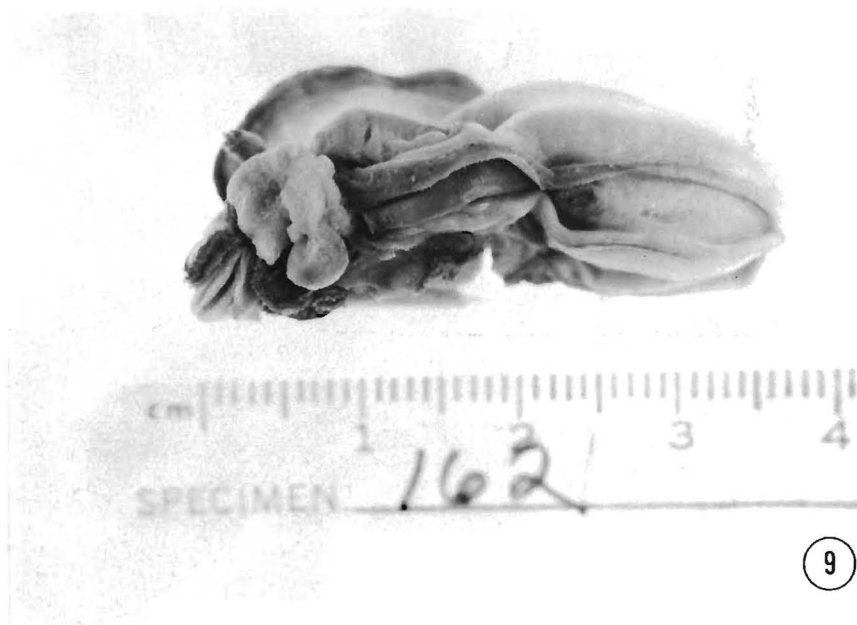

Figure 9.—Nodular growth with granular texture attached to mantle.



Figure 10.—Growth resembling clusters of grapes attached to mantle.

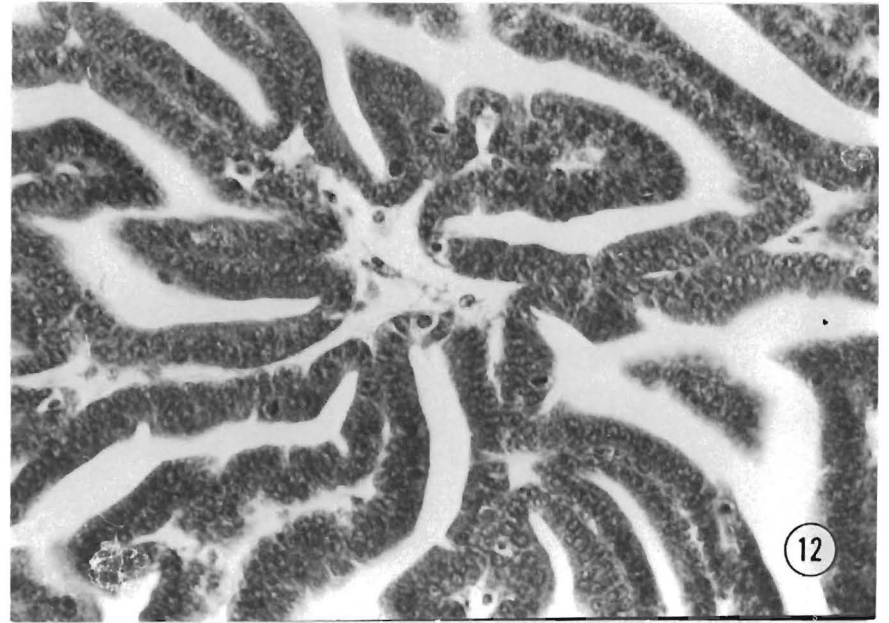


Figure 12.—Numerous mitotic figures indicate rapid growth. 160 \times .

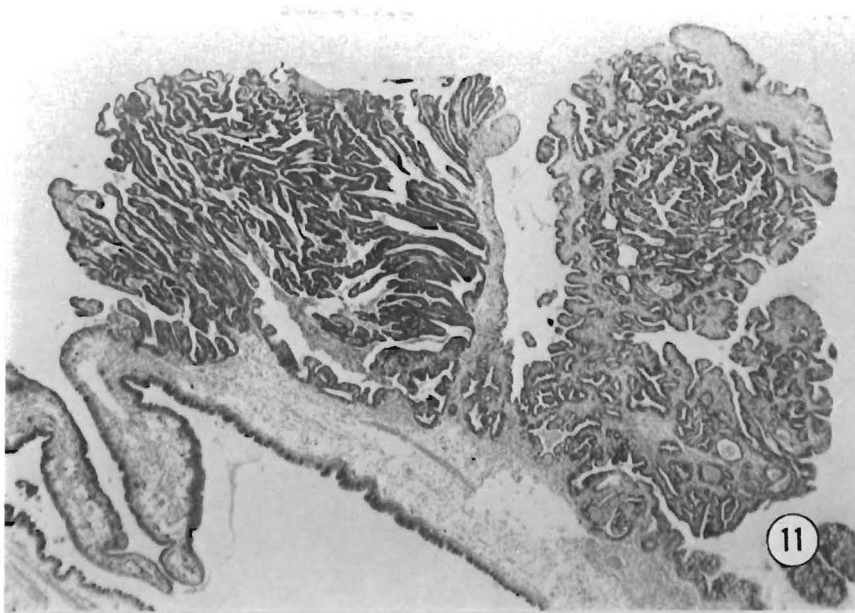


Figure 11.—Tumor nodules continuous with mantle epithelium. 13 \times .

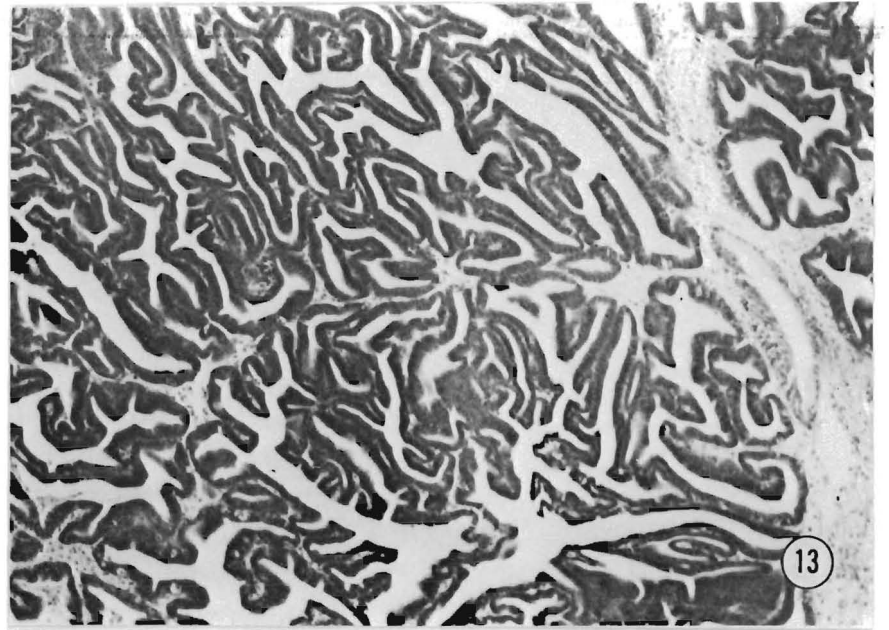


Figure 13.—Plexiform growth pattern. 25 \times .

to the Registry of Tumors in Lower Animals (RTLA 771) by John G. Dennison of the Olympic Research Division, ITT Rayonier, Incorporated, in March 1973. Gross and histological study showed it to be similar to lesions previously described in *C. gigas* (Sparks, et al., 1964; Sparks, Pauley, and Chew, 1969) and in *C. virginica* (Smith, 1934). The gross specimen had a firm but pliable, dull white, lobulated growth 2.5 cm in diameter attached to the mantle by a slender peduncle 1 cm in length (Figs. 5, 6). Despite the loss of some microscopic detail due to autolysis, vesicular connective tissue cells were readily discerned to comprise the major component of the growth. These cells, which were arranged singly, in bunches, and in pseudorosettes around blood vessels (Fig. 7) had tiny central nuclei surrounded by large fully expanded vesiculated cytoplasm suggesting that a large amount of glycogen had been present prior to processing. The tumor cells were indistinguishable from the normal vesicular connective tissue cells located in the usual position next to the digestive gland of the specimen (Fig. 8) although they were supported by a considerably larger fibrous stroma. The epithelial lining consisted of simple columnar cells interspersed with goblet cells similar to normal mantle except for deep crypts in some areas. Mitoses were not seen in any of the components.

In conclusion, the lesion appeared to be composed of slow-growing, noninvasive, well-differentiated vesicular connective tissue associated with abundant, possibly reactive, fibrous tissue enclosed by a simple, occasionally cryptic epithelium composed of normal appearing cells. It is interpreted as a benign vesiculo-epithelial polyp.

CASE III: EPITHELIAL PAPILLOMAS OF THE MANTLE OF ROCK OYSTERS, *CRASSOSTREA COMMERCIALIS*

During the last 11 years over 140 rock oysters, *Crassostrea commercialis*, with papillary growths arising from mantle epithelium were collected by Peter H. Wolf from several populations within the Hawkesbury and Shoalhaven River estuaries of Australia (Wolf, 1974). This is a prevalence of less than 0.001 percent which is prob-

ably low since the survey was conducted by oyster shuckers incidental to their regular duties. Both estuaries drain agricultural land, support moderate pleasure boating, and one receives effluent from a pulp mill several miles upstream but other than that, neither estuary receives industrial effluent. Limited electron microscopy has not revealed viruses. So far attempts to transplant the growths have not been successful (Wolf, 1976).

Two whole specimens contributed by Wolf to the Registry of Tumors in Lower Animals (RTLA 160 and 162) had features similar to those already described (Wolf, 1969, 1971, 1976). Grossly RTLA 162 was a nodular growth with a granular texture measuring 8 × 5 × 4 mm (Fig. 9) while RTLA 160, which was 7 × 5 mm, had the appearance of several clusters of various sized grapes (Fig. 10).

Microscopically the lesions were continuous with normal mantle epithelium (Fig. 11). However, tumor cells were more basophilic and exhibited a higher than normal nucleus to cytoplasm ratio. Mitoses were extremely numerous (Fig. 12), 28 being counted in one 400× field. This rapid growth had resulted in a random buckling which produced a plexiform pattern of paired epithelial cells separated by a thin fibrous stroma (Fig. 13). The growths were focal in nature but strands of muscle that normally underlie muscle epithelium had been drawn into the tumor confirming local invasion. Exfoliated necrotic epithelial cells associated with macrophages were abundant in some areas. These lesions were

interpreted as epithelial papillomas of the mantle.

LITERATURE CITED

- Pauley, G. B. 1967a. Four freshwater mussels (*Anodonta californiensis*) with pedunculated adenomas arising from the foot. *J. Invertebr. Pathol.* 9:459-466.
- _____. 1967b. A tumorlike growth on the foot of a freshwater mussel (*Anodonta californiensis*). *J. Fish. Res. Board Can.* 24:679-682.
- _____. 1969. A critical review of neoplasia and tumorlike lesions in mollusks. *In Neoplasms and related disorders of invertebrate and lower vertebrate animals.* Natl. Cancer Inst. Monogr. 31:509-539.
- Smith, G. M. 1934. A mesenchymal tumor in an oyster (*Ostrea virginica*). *Am. J. Cancer* 22:838-841.
- Sparks, A. K. 1972. Tumors and tumorlike conditions in invertebrates. Phylum Mollusca. *In Invertebrate pathology. Noncommunicable diseases,* p. 304-357. Academic Press, N.Y.
- Sparks, A. K., G. B. Pauley, R. R. Bates, and C. S. Sayce. 1964. A mesenchymal tumor in a Pacific oyster, *Crassostrea gigas* (Thunberg). *J. Insect Pathol.* 6:448-452.
- Sparks, A. K., G. B. Pauley, and K. K. Chew. 1969. A second mesenchymal tumor from a Pacific oyster (*Crassostrea gigas*). *Proc. Natl. Shellfish. Assoc.* 59:35-39.
- Wolf, P. H. 1969. Neoplastic growth in two Sydney rock oysters, *Crassostrea commercialis* (Iredale and Roughley). *In Neoplasms and related disorders of invertebrate and lower vertebrate animals.* Natl. Cancer Inst. Monogr. 31:563-573.
- _____. 1971. Unusually large tumor in a Sydney rock oyster. *J. Natl. Cancer Inst.* 46:1079-1084.
- _____. 1974. Integumentary neoplasms in oysters. *In Abstracts: XIth International Cancer Congress, 20-26 October 1974, Florence (Italy), Vol. 2, p. 171.*
- _____. 1976. Studies on the geographical distribution, etiology and transmission of integumentary epitheliomas in rock oysters from Australian estuaries. *In F. Homburger (editor), Progress in experimental tumor research, Vol. 20, Neoplasms in aquatic animals as indicators of environmental carcinogens.* Karger, Basel.

MFR Paper 1209. From Marine Fisheries Review, Vol. 38, No. 10, October 1976. Copies of this paper, in limited numbers, are available from D825, Technical Information Division, Environmental Science Information Center, Washington, DC 20235. Copies of Marine Fisheries Review are available from the Superintendent of Documents, U.S. Government Printing Office, Washington, DC 20402 for \$1.10 each.