

- FEDER, H. M., C. H. TURNER, AND C. LIMBAUGH.
1974. Observations on fishes associated with kelp beds in southern California. Calif. Dep. Fish Game, Fish Bull. 160, 144 p.
- HUBBS, C. L.
1921. The ecology and life-history of *Amphigonopterus aurora* and other viviparous perches of California. Biol. Bull. (Woods Hole) 40:181-209.
- LAGIOS, M. D.
1965. Seasonal changes in the cytology of the adenohypophysis, testes, and ovaries of the black surfperch, *Embiotoca jacksoni*, a viviparous percomorph fish. Gen. Comp. Endocrinol. 5:207-221.
- RECHNITZER, A. B., AND C. LIMBAUGH.
1952. Breeding habits of *Hyperprosopon argenteum*, a viviparous fish from California. Copeia 1952:41-42.
- SHAW, E., J. ALLEN, AND R. STONE.
1974. Notes on collection of shiner perch, *Cymatogaster aggregata* in Bodega Harbor, California. Calif. Fish Game 60:15-22.
- TURNER, C. L.
1938. Histological and cytological changes in the ovary of *Cymatogaster aggregatus* during gestation. J. Morphol. 62:351-373.
- WIEBE, J. P.
1968. The reproductive cycle of the viviparous seaperch, *Cymatogaster aggregata* Gibbons. Can. J. Zool. 46:1221-1234.

STEPHEN R. GOLDBERG
WILLIAM C. TICKNOR, JR.

Department of Biology
Whittier College
Whittier, CA 90608

GALLBLADDER LESIONS IN CULTURED PACIFIC SALMON

This note records observations on a previously unreported biliary lesion in the gallbladders of various samples of coho, *Oncorhynchus kisutch*; chinook, *O. tshawytscha*; and sockeye, *O. nerka*, salmon cultured mainly in Puget Sound, Wash., during 1974-76. There were no obvious signs of distress or physical debilitation in affected fish. The gallbladders were enlarged and impacted with an amorphous yellow or white material which, in some instances, extended into the common bile duct (Figure 1).

Efforts to prove infectious origin were unsuccessful. No bacteria were consistently isolated from gallbladder or hepatic tissues and attempts to demonstrate a viral agent on a chinook cell line were negative. Possibilities of protozoan or helminth parasitism were discounted after micro-

scopic examination of tissues, gallbladder, and intestinal contents.

Normal and impacted gallbladder, liver, and kidney tissues were fixed in 10% buffered Formalin¹ and stained sections were prepared at Northwest and Alaska Fisheries Center (NWAFC), NMFS, NOAA, Seattle, Wash. Excessive vacuolation of the columnar epithelium was evident in affected gallbladders (Figure 2). No lesions were observed in either the livers or kidneys of fish with the gallbladder condition.

Preliminary studies (Table 1) indicate a predominance of an as yet uncharacterized mucopolysaccharide material in impacted gallbladders. Serum bilirubin, cholesterol, and glucose concentrations of coho salmon with impacted gallbladders were not different from those found in normal fish.

TABLE 1.—Composition of material in impacted gallbladders in coho salmon.

Material	Percentage
Solids (dry wt @ 105°C)	30.4
Ash	14.2
Nitrogen	1.25
Reducing sugar (ortho-toluidine method)	11.52

Case History

Impacted gallbladders were first observed in May 1974, when 25 yearling coho salmon from saltwater pens in southern Puget Sound were referred to the disease laboratory at NWAFC Aquaculture Experiment Station near Manchester, Wash., for diagnosis of an unrelated skin infection (Table 2). The condition was detected in four separate lots of coho and chinook salmon in central Puget Sound during the summer growing season of 1974. In July 1975, the lesion was seen in a subsample of 250 chinook salmon smolts in a private freshwater rearing pond in Oregon (Table 2). Several lots of salmon being held for husbandry and disease research at the Aquaculture Experiment Station have also been found to have this condition.

Four thousand 0-age coho salmon smolts (18-20 g) reared on commercially prepared Oregon Moist Pellets (OMP) were transferred to saltwater pens at the Aquaculture Experiment Station in early August 1976 where they continued to receive the same ration. Smolts of the same stock (1,000) were

¹Reference to trade names does not imply endorsement of the National Marine Fisheries Service, NOAA.




FIGURE 1.—Impacted material can be clearly seen in the gallbladder of affected coho salmon (upper fish). Normal gallbladder (lower fish) is shown for comparison.

TABLE 2.—Occurrence of impacted gallbladders in Pacific salmon subsampled from saltwater and freshwater rearing areas.

Date	Species	Age	Feed	No. of fish in lot	No. of fish examined	Percentage of fish examined with gallbladder anomalies	Environment and site
May 1974	Coho	1+	OMP ¹	—	25	100	Net pens: South Puget Sound
Oct. 1974	Coho	1+	OMP	100,000	100	90	Net pen: Central Puget Sound
Oct. 1974	Coho	1+	OMP	100,000	100	76	Net pen: Central Puget Sound
Oct. 1974	Coho	1+	OMP	100,000	165	90	Net pen: Central Puget Sound
Oct. 1974	Chinook	0+	OMP	100,000	157	89	Net pen: Central Puget Sound
July 1975	Chinook	0+	OMP	50,000	250	90	Freshwater holding pond: lower Columbia River
Aug. 1975	Sockeye	1+	OMP	450	39	85	Net pen: Research fish, Manchester, Wash.
Sept. 1975	Coho	1+	OMP	250	160	93	Net pen: Research fish, Manchester
Nov. 1975	Coho	1+	OMP	164	164	85	Net pen: Research fish, Manchester
Nov. 1975	Coho	1+	Dry ²	9,000	600	0	Net pen: Central Puget Sound
Dec. 1975	Chinook	2+	OMP	40	40	0	Cultured brood stock: Manchester
Dec. 1975	Coho	2+	OMP	94	94	0	Cultured brood stock: Manchester
Dec. 1975	Coho	3	Natural	25	25	0	Mature fish returning from sea: Manchester
Dec. 1975	Coho	1+	OMP	500	200	0	Freshwater station: Seattle, Wash.
Jan. 1976	Coho	1+	SC ³	400	40	0	Freshwater station: Seattle
Jan. 1976	Coho	1+	OMP	66,000	60	99	Net pen: Research fish, Manchester
Oct. 1976	Coho	1+	OMP	1,600	120	75	Net pen: Research fish, Manchester
Oct. 1976	Coho	0+	OMP	1,000	100	0	Freshwater station: Seattle
Oct. 1976	Coho	0+	OMP	4,000	180	38	Net pen: Research fish, Manchester
Aug.—Oct. 1976	Coho	1+	Dry	100,000+	114	37	Net pen ⁴ : Central Puget Sound

¹Oregon Moist Pellet — Commercial product.

²Commercial dry pelleted ration.

³Fish fed experimental OMP diet containing single cell protein.

⁴Pers. commun., D. Weaver, Domsea Farms, Gorst, Wash.

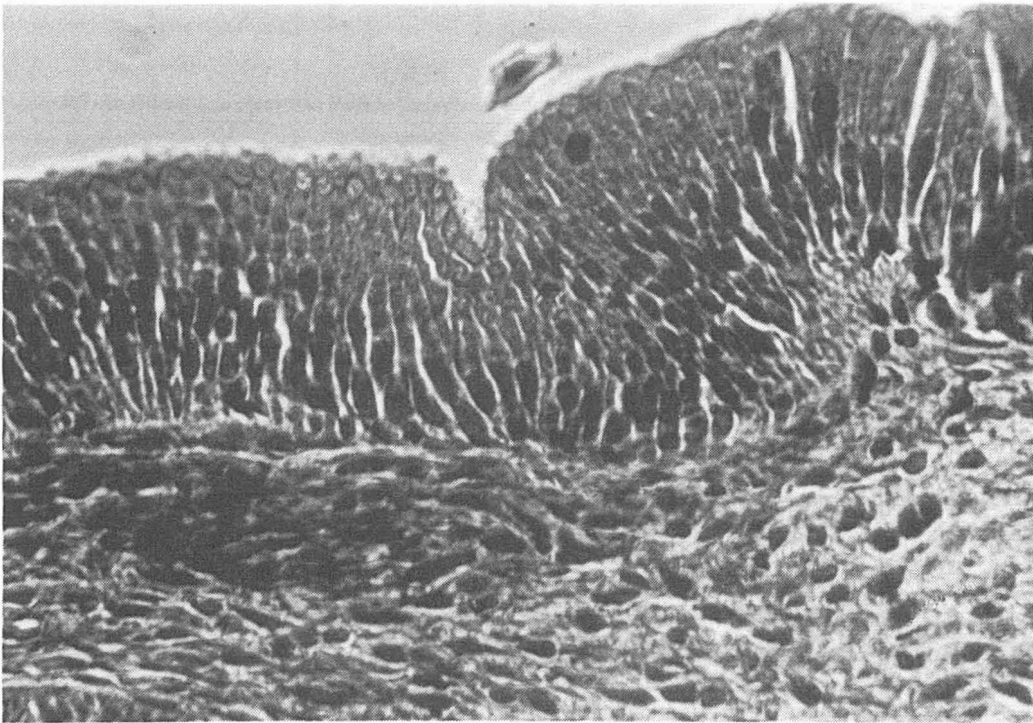
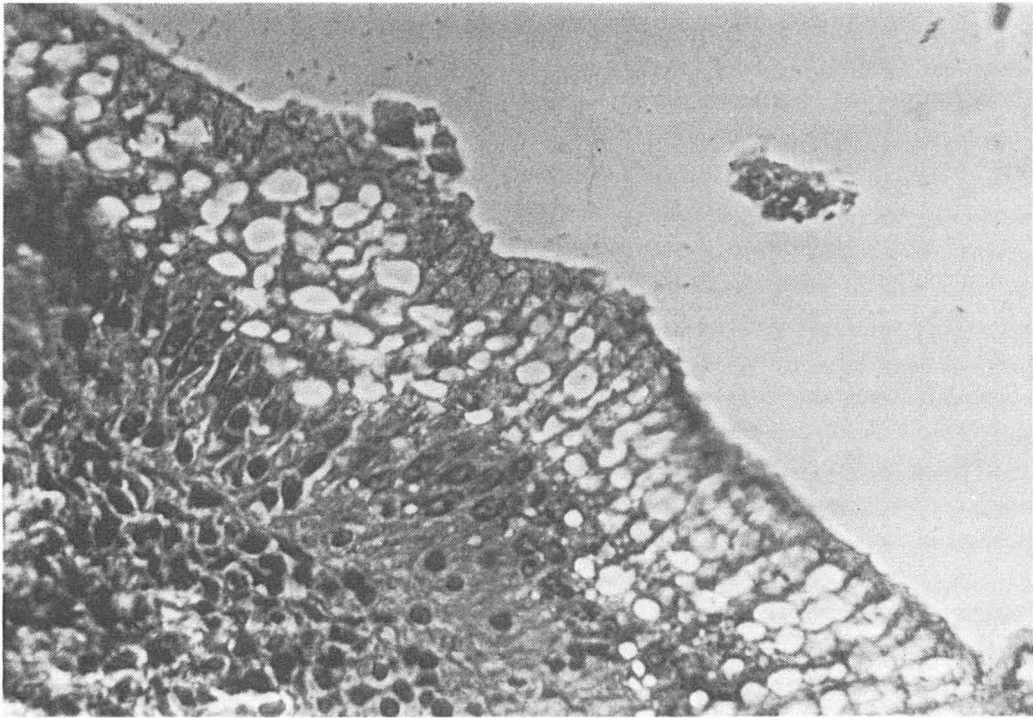


FIGURE 2.—Upper photo shows histopathologic features (vacuolation) of the epithelium from an impacted gallbladder of a small coho salmon cultured in saltwater. Lower photo shows normal epithelium of the gallbladder from a small wild coho salmon collected in saltwater. Hematoxylin-eosin stain; $\times 320$.

held back for freshwater rearing. Approximately 38% of the fish in saltwater were found to have the gallbladder condition by mid-October. The condition did not develop in those remaining in freshwater.

In all cases observed thus far, affected fish were young (<2 yr) salmon that had been reared exclusively on commercially prepared pellets. With the exception of the occurrence in Oregon, all cases of the abnormality have occurred in saltwater net pens.

With dietary adjustments the condition is apparently reversible. In an unrelated nutrition study, 75% of the subsamples of one lot of 1,800 coho salmon that had been fed a ration of OMP for several months had impacted gallbladders. These test fish were divided into two lots. One group (1,400) was fed a laboratory prepared moist pellet diet and the remaining fish (400) were continued on the commercial OMP diet. After 4 mo, subsamples indicated that incidence of abnormal gallbladders in fish on the laboratory diet had been reduced to 5%. Incidence of the condition in the test group maintained on the OMP diet remained at 75%.

Discussion

I have found no published information relative to gallbladder abnormalities in fishes. The pathological features described for this condition do not resemble any infectious disease currently described for fishes and are more suggestive of a toxic or nutritional disorder.

The biliary system is an integral part of the digestive apparatus, playing an important role in lipid digestion. It also provides a mechanism for recycling certain metabolic byproducts of hepatic origin through the digestive system. Many of these metabolic byproducts are excretory wastes while others can be salvaged for reuse by redigestion. Studies as yet do not prove a major detrimental effect of this condition on the fish. Knowing the importance of the biliary system, however, it is inconceivable that it does not have an adverse effect on the animals' nutritional status, particularly in relation to systems dependent upon adequate and diverse lipid supply.

Acknowledgments

I thank Kenneth Pierce, graduate student, University of Washington, Seattle; for preparing the

gallbladder specimens for histological examination.

LEE W. HARRELL

Northwest and Alaska Fisheries Center
National Marine Fisheries Service, NOAA
2725 Montlake Boulevard East
Seattle, WA 98112

TIMING OF THE SURFACE-TO-BENTHIC MIGRATION IN JUVENILE ROCKFISH, *SEBASTES DIPLOPROA*, OFF SOUTHERN CALIFORNIA

Species of the genus *Sebastes* lead a pelagic existence as larvae, transforming to pelagic prejuveniles and finally benthic juvenile stages at varying sizes (Moser 1967, 1972). Pelagic prejuveniles of some species often congregate under drifting objects (Hitz 1961); off the coast of southern California, *Sebastes diploproa* (Gilbert 1890) is the dominant rockfish species found under drifting kelp (Mitchell and Hunter 1970). Adults of this species inhabit a bathymetric range of 91–578 m and a latitudinal range from Alaska to Baja California (Hart 1973). Little is known about the movement of this rockfish from surface to benthic waters. This paper provides information on the disappearance from surface waters and the appearance in the benthic habitat based on seasonal size distribution from the two habitats.

Materials and Methods

Surface prejuveniles were collected by dip net off San Diego, Calif. (lat. 32°52'N, long. 117°30'W), from beneath drifting kelp (primarily *Macrocystis pyrifera*) during 1975 and 1976. Benthic juveniles were sampled in standard 10-min bottom trawls with a 7.6-m (25-ft) otter trawl (12.7-mm stretch mesh cod end liner) in 1972 through 1976. Most trawls were made in and around the Los Angeles Bight from Point Dume (lat. 34°00'N, long. 118°48'W) to Dana Point (lat. 33°28'N, long. 117°43'W) at depths from 92 to 183 m, although small *S. diploproa* were captured as shallow as 46 m. This does not encompass the entire adult bathymetric range, but younger stages of *Sebastes* generally tend to occupy shallower parts of the adult range (Kelly and Barker 1961; Moser 1967, 1972; Westrheim 1970). Only