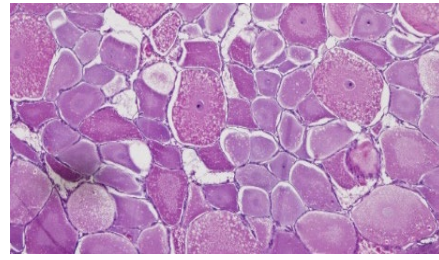
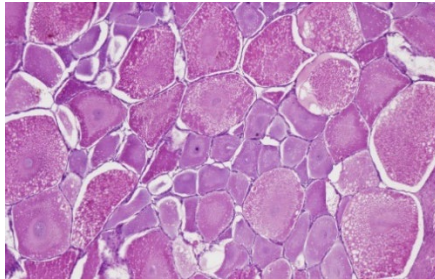


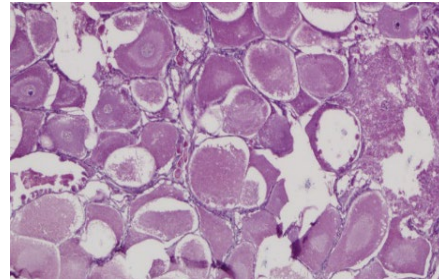
(A) Immature



(B) Early maturing

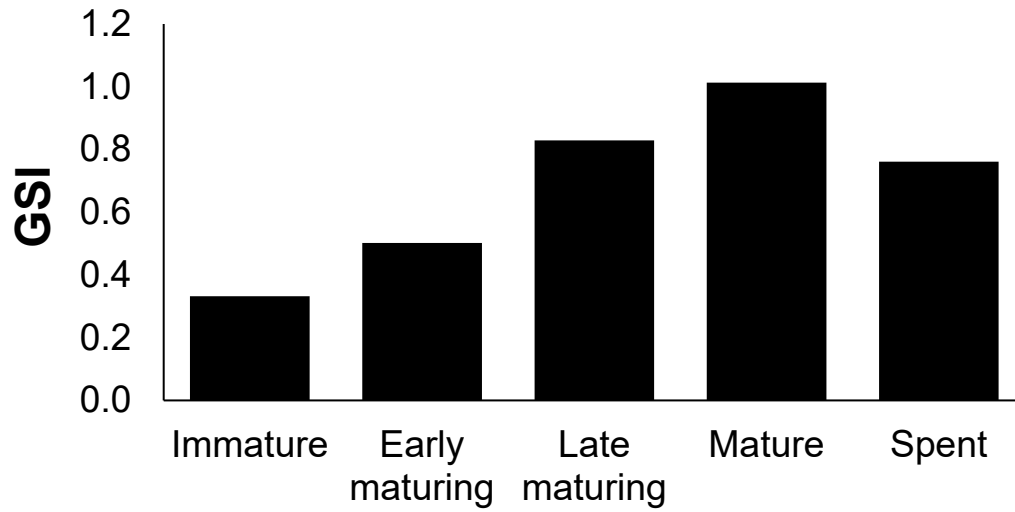


(C) Mature



(D) Spent

Supplementary Figure 1. Histological images of the maturity stages of female flathead lobsters (*Thenus orientalis*) collected during 2013–2016 from the waters of Saudi Arabia in the Arabian Gulf. The four stages shown in this figure are **(A)** immature, developing oocytes; **(B)** early maturing, vitellogenesis with reduced nuclei; **(C)** mature, mature ova with few developing oocytes; and **(D)** spent, flacid with interstitial spaces and few eggs and maturing ova.



Supplementary Figure 2. Variations in the frequencies of maturity stages of female flathead lobsters (*Thenus orientalis*) collected during 2013–2016 from the waters of Saudi Arabia in the Arabian Gulf.